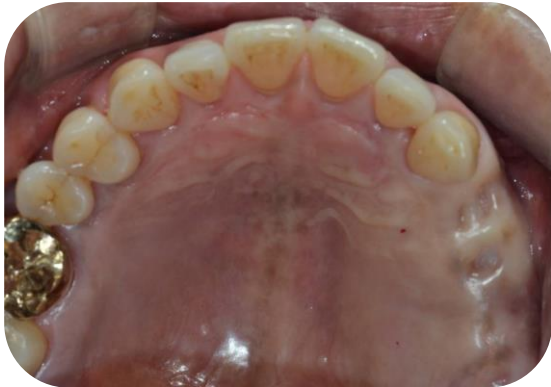

AnyOne

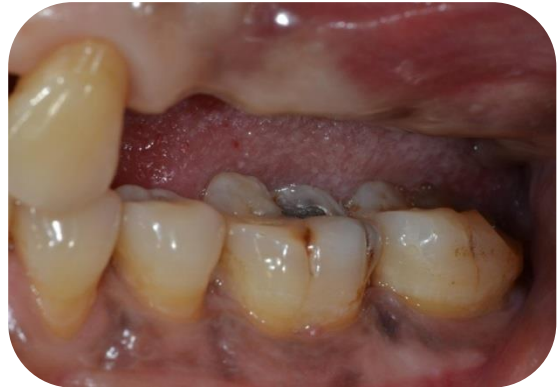CLINICAL CASE REPORT

Dr. Kyung Ho, Ryoo
(Gwangju MIR Dental Hospital)

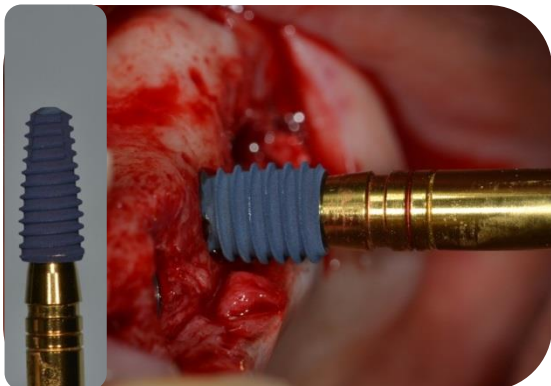
■ Clinical Case I . Dr. Gyeong-Ho Ryoo, Gwangju MIR Dental Hospital



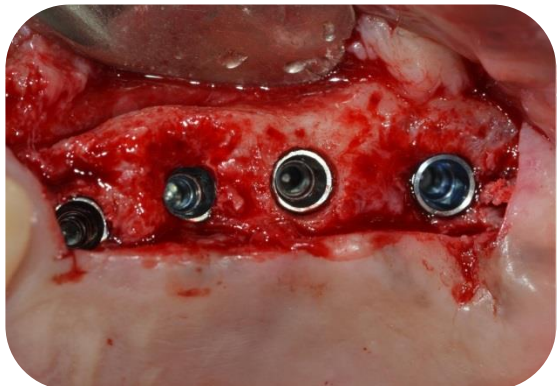
Preoperative Photograph(2011.10.22)



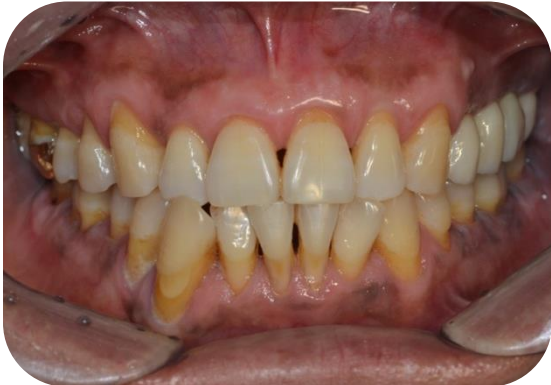Preoperative Photograph



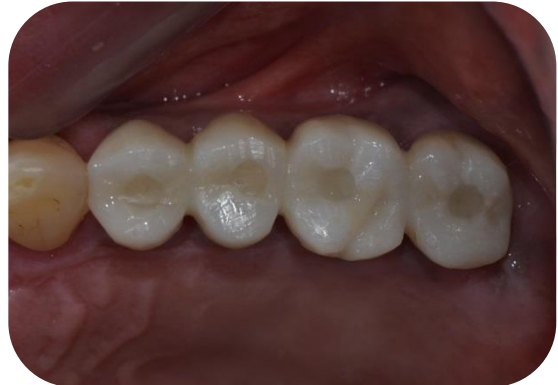AnyOne (Xpeed surface) Implant Installation



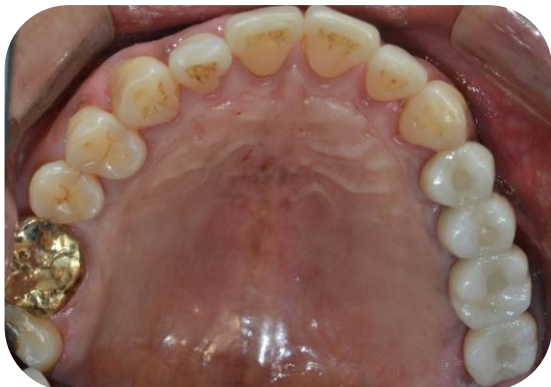AnyOne in position



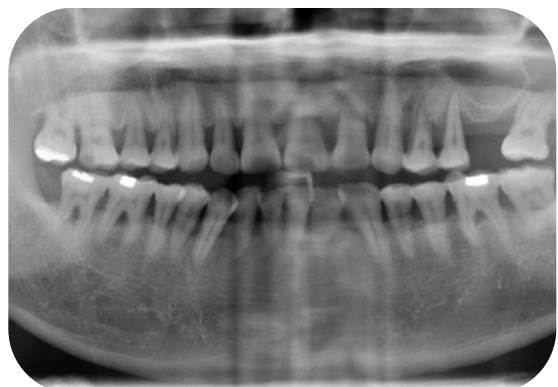After final loading



After final loading

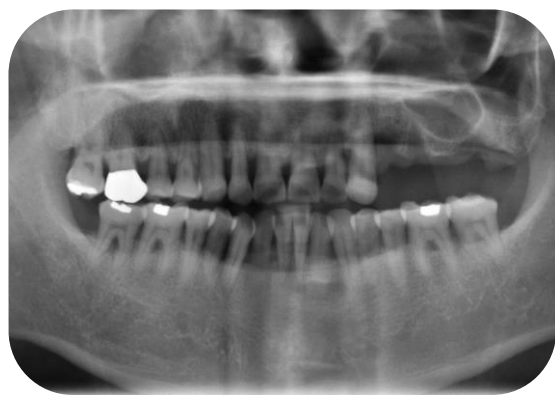


After final loading

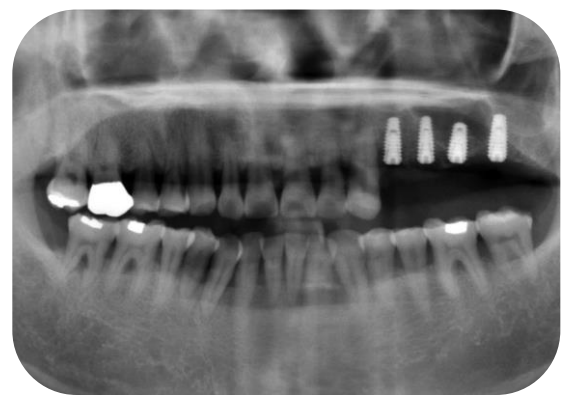

Preoperative panoramic radiograph (2011.10.22)

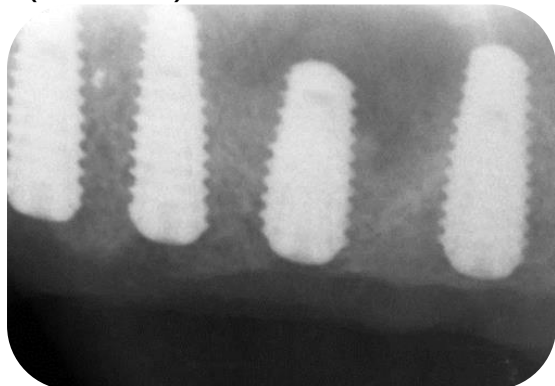
■ Clinical Case I . Dr. Gyeong-Ho Ryoo, Gwangju MIR Dental Hospital



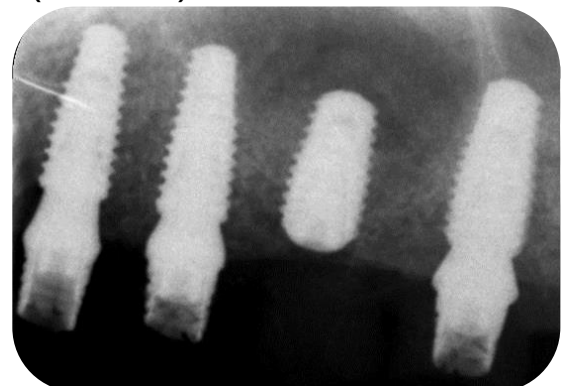Preoperative panoramic radiograph
(2011.12.26)



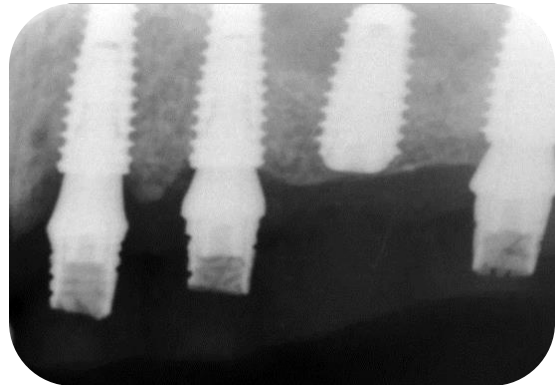
Postoperative panoramic radiograph
(2012.02.25)



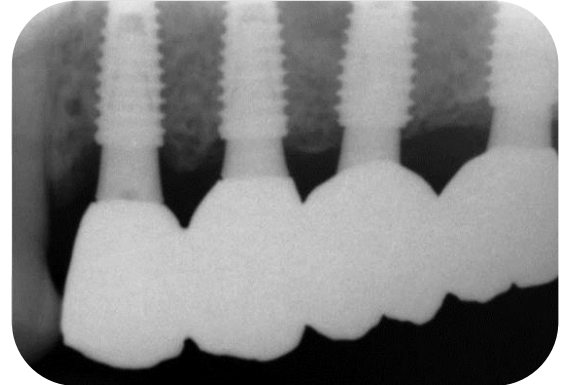
Intra-oral radiograph (2012.05.19)



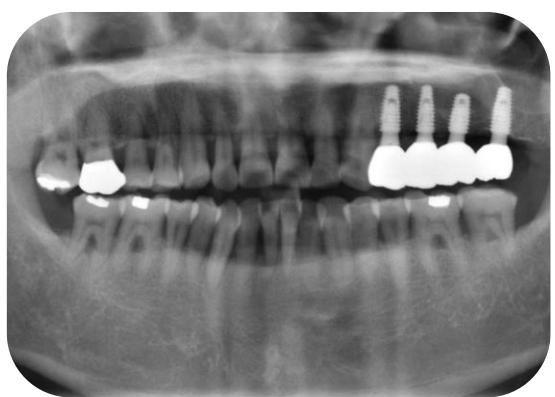
Intra-oral radiograph (2012.06.02)



Intra-oral radiograph (2012.08.25)



Intra-oral radiograph (2012.11.26)



Postoperative panoramic radiograph
(2013.02.18)