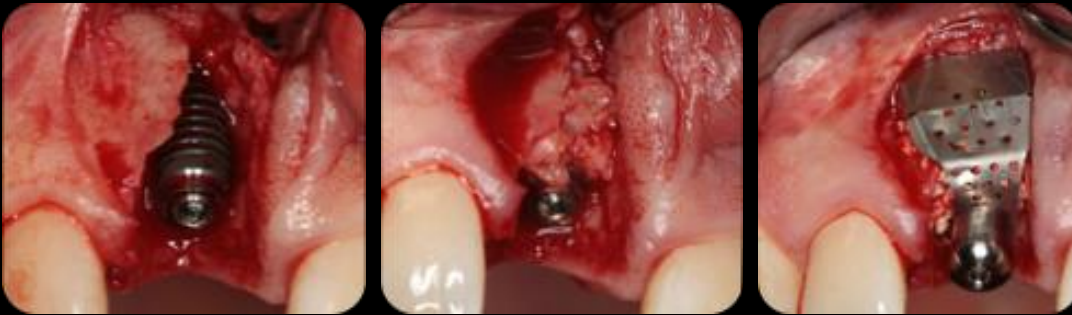

AnyRidge & i-Gen



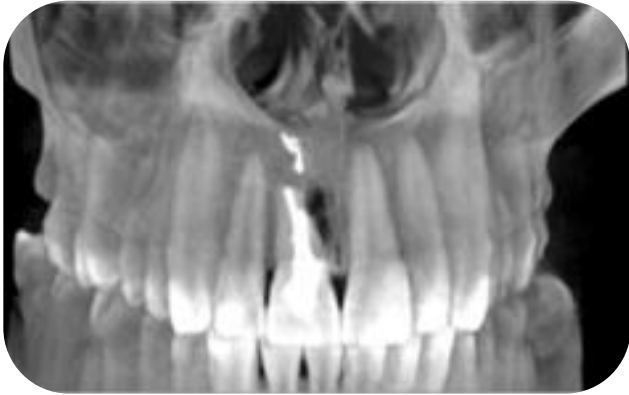CASE REPORT



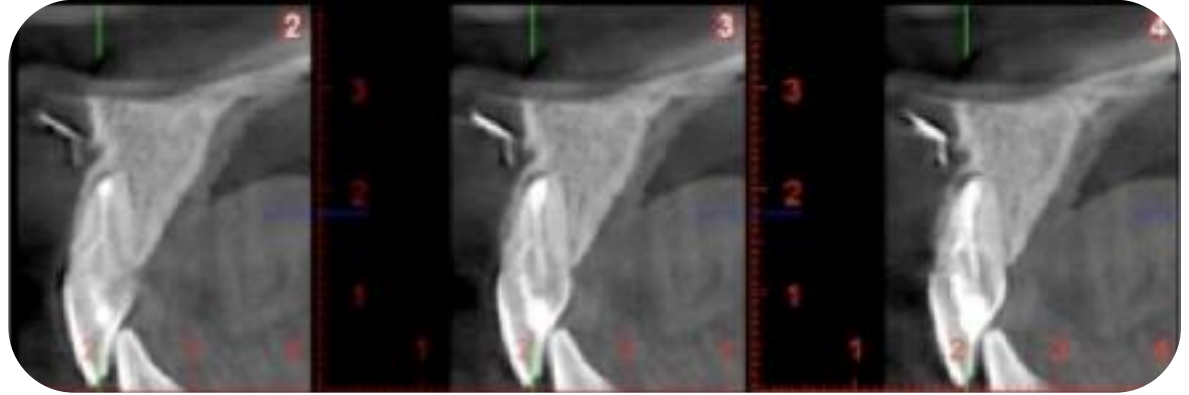
Name: **Dr. Iulian Filipov**
Opera Dental Clinique

Nation: **Romania**

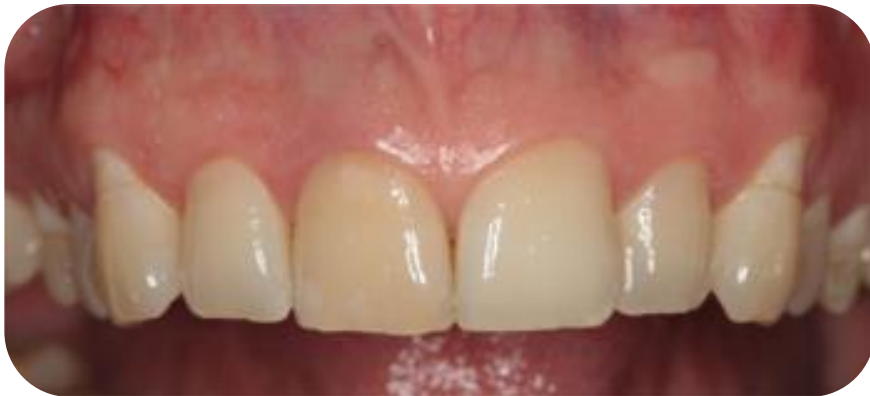



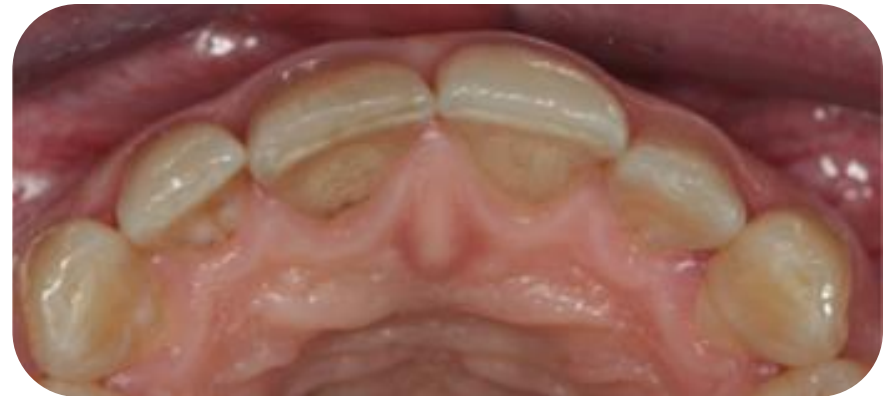CT scan



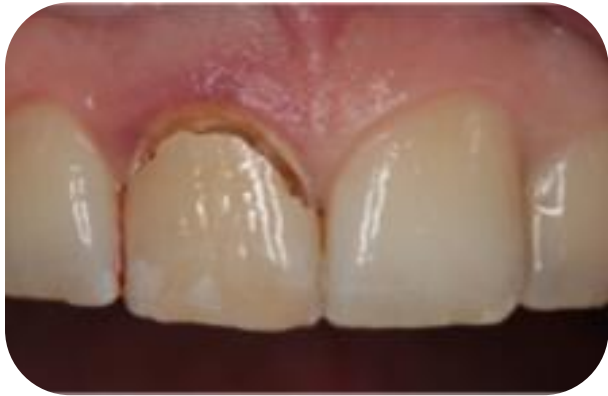
Endo filling material present within soft tissue



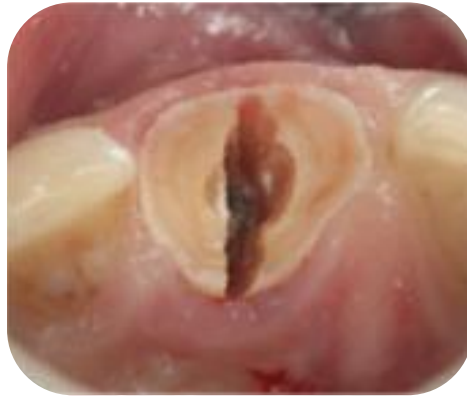Clinical view (labial view)



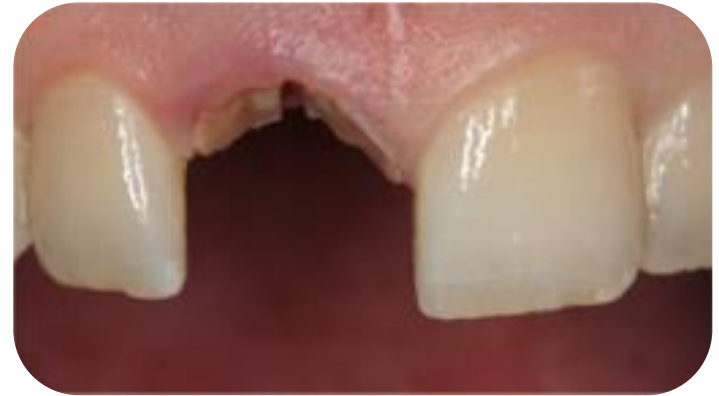Clinical view (occlusal view)



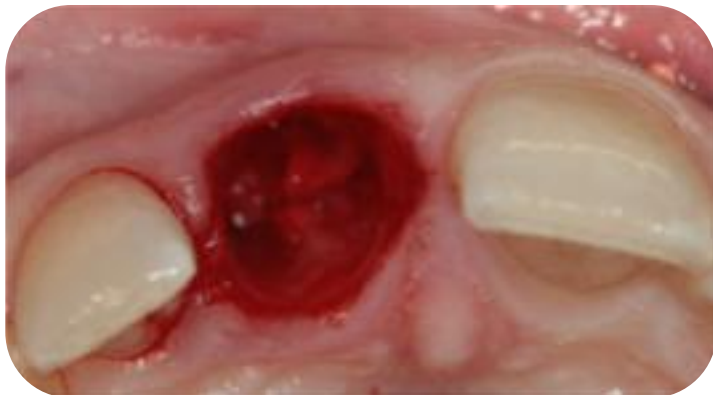Tooth preservation



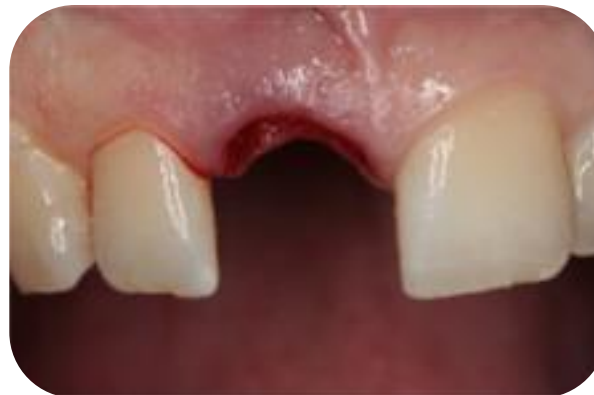Atraumatic extraction
(occlusal view)



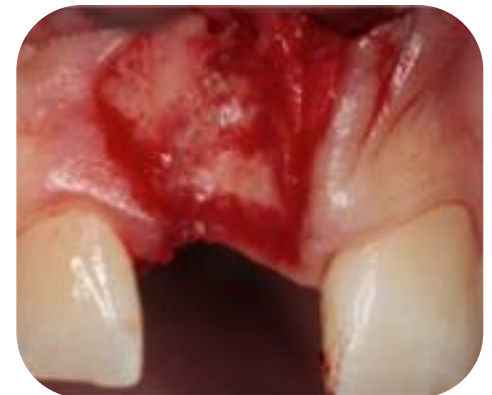Atraumatic extraction
(labial view)



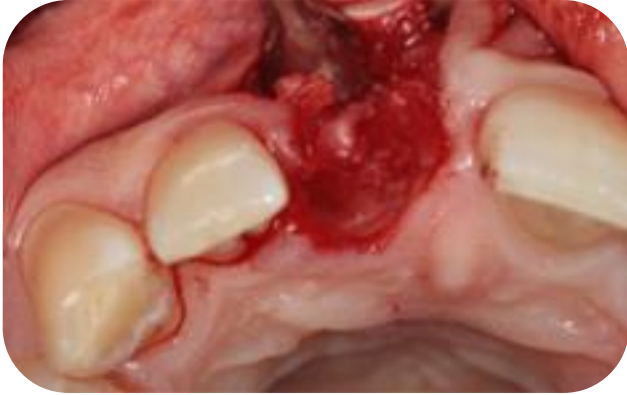Alveola (occlusal view)



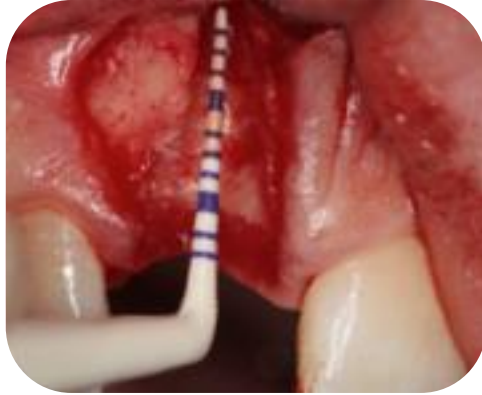Alveola (labial view)



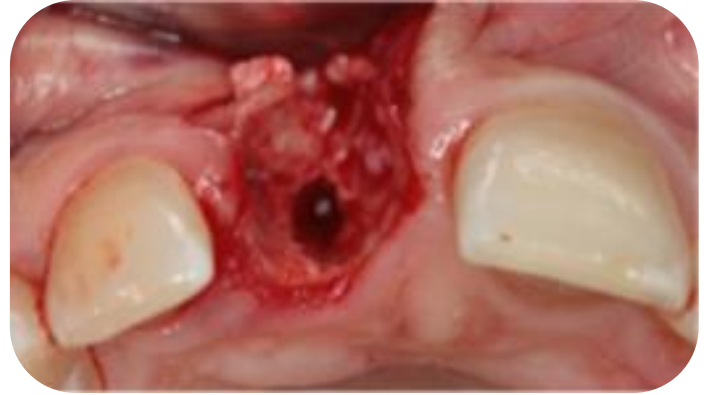Single vertical incision



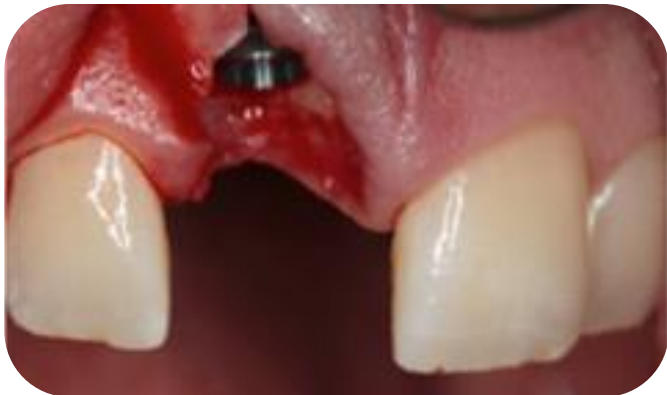Mucoperiosteal flap raised



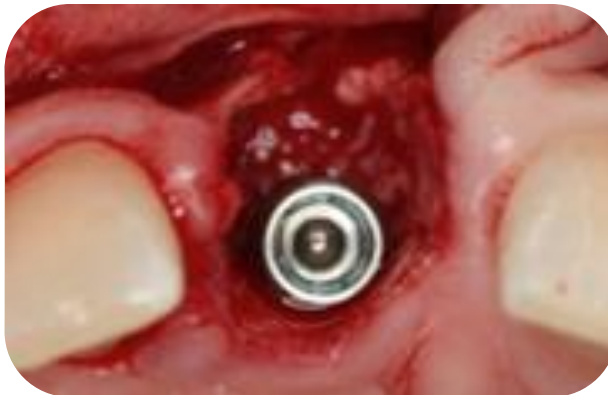Cortical plate defect measurement



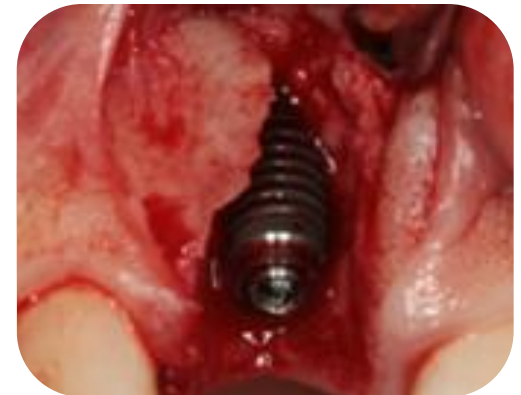Neo-alveola preparation



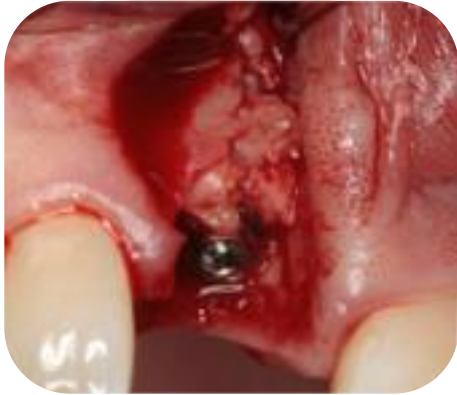Implant in place



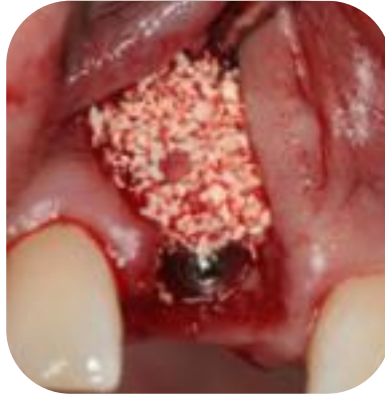Implant palatal position



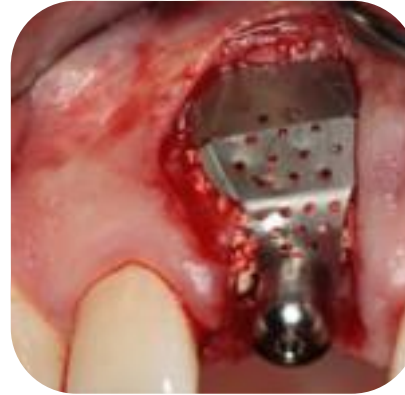Labial defect



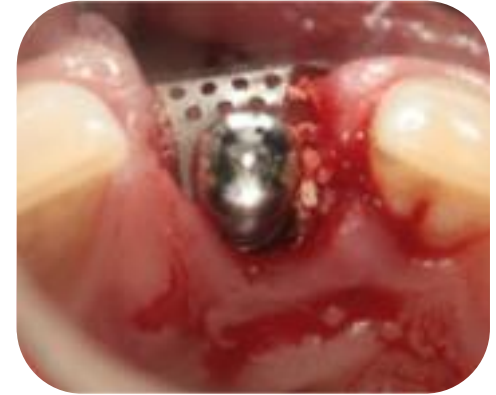Bone chips from tuberosity



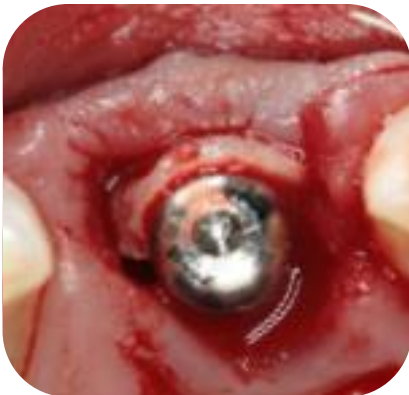Xenograft



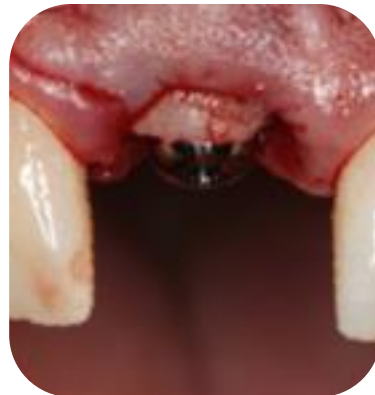i-Gen (labial aspect)



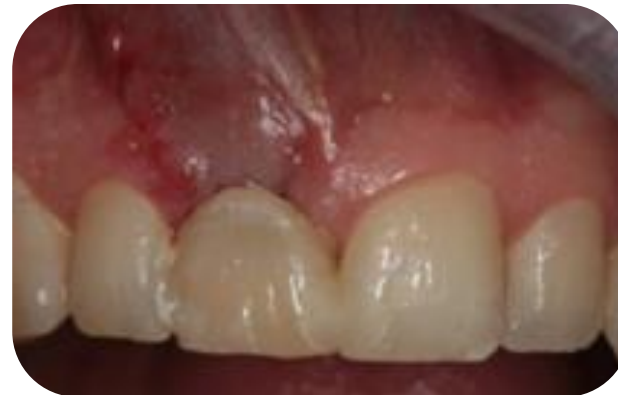i-Gen (occlusal aspect)



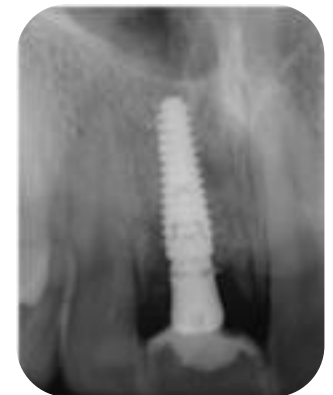CTG from tuberosity



Placed 1 mm above gingival margin



Natural tooth adapted to new local conditions (7 days after surgery)



Postop x-ray