

International Multi-Center Study for the Megagen Anyridge Implant System



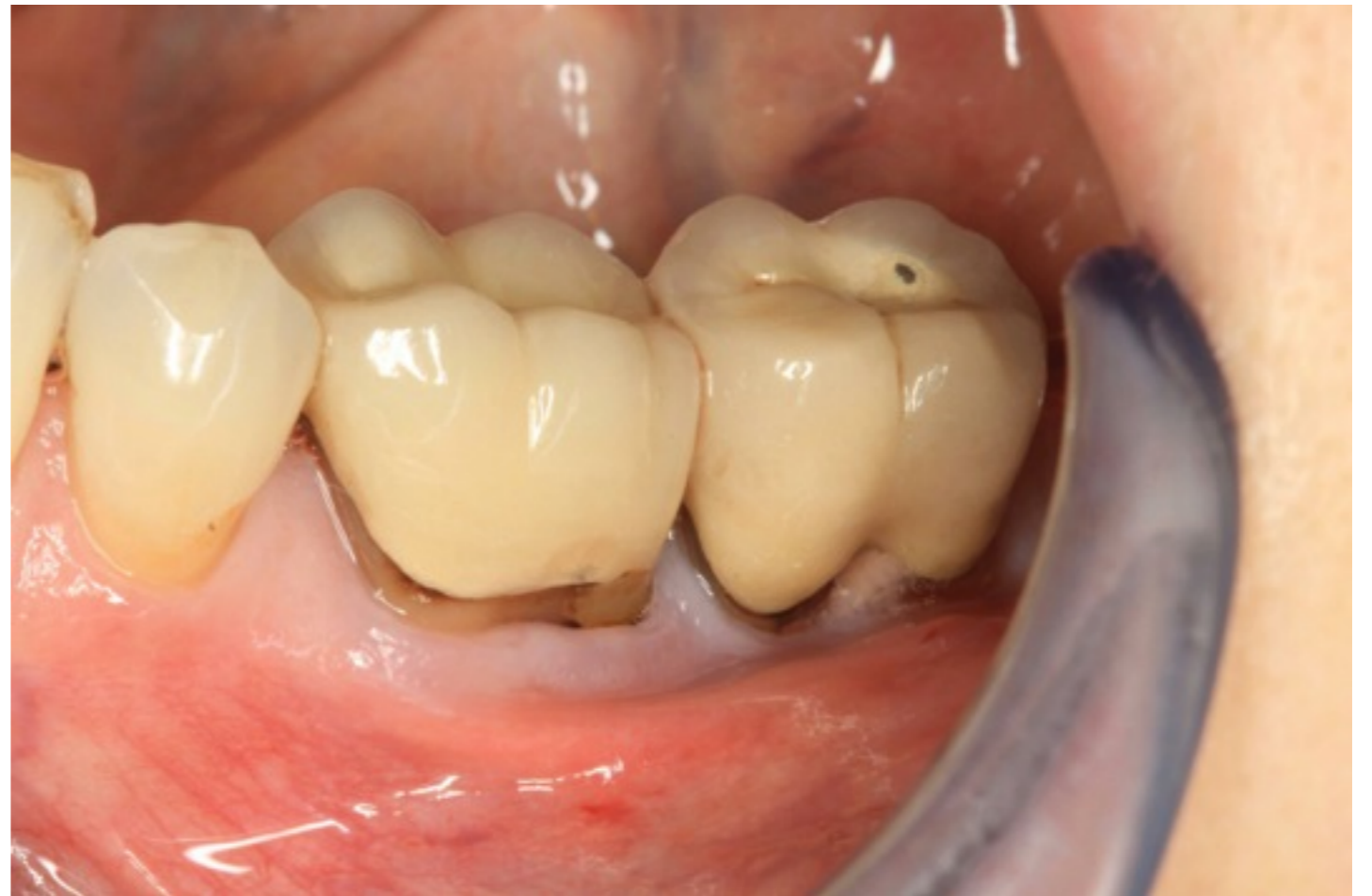Case Presentation

Dr Howard Gluckman
Cape Town
South Africa

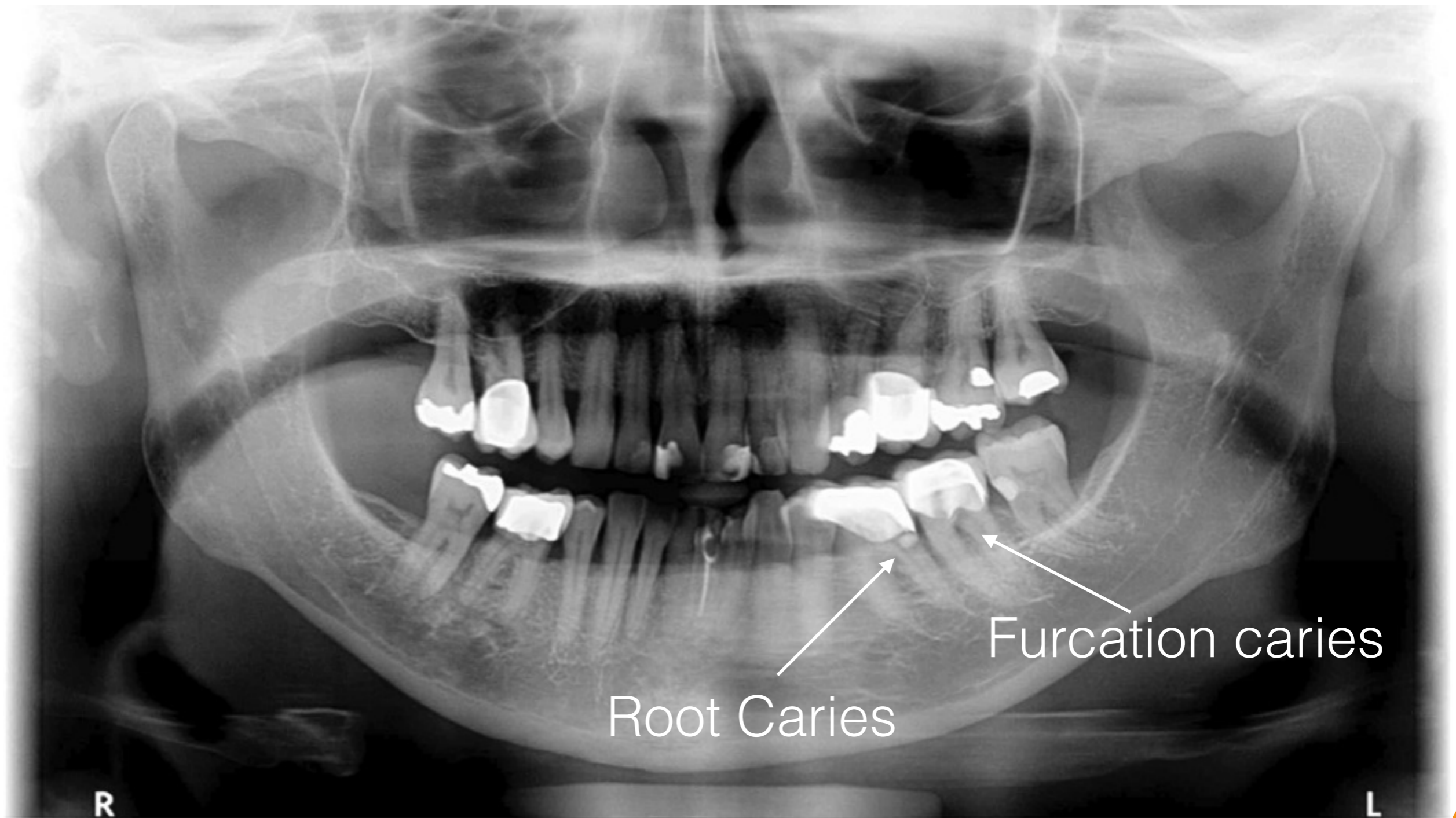


Patient Details

- MC: The patient presented with pain in both lower left molars.
- Clinical Examination showed subgingival root caries which extended into the furcation



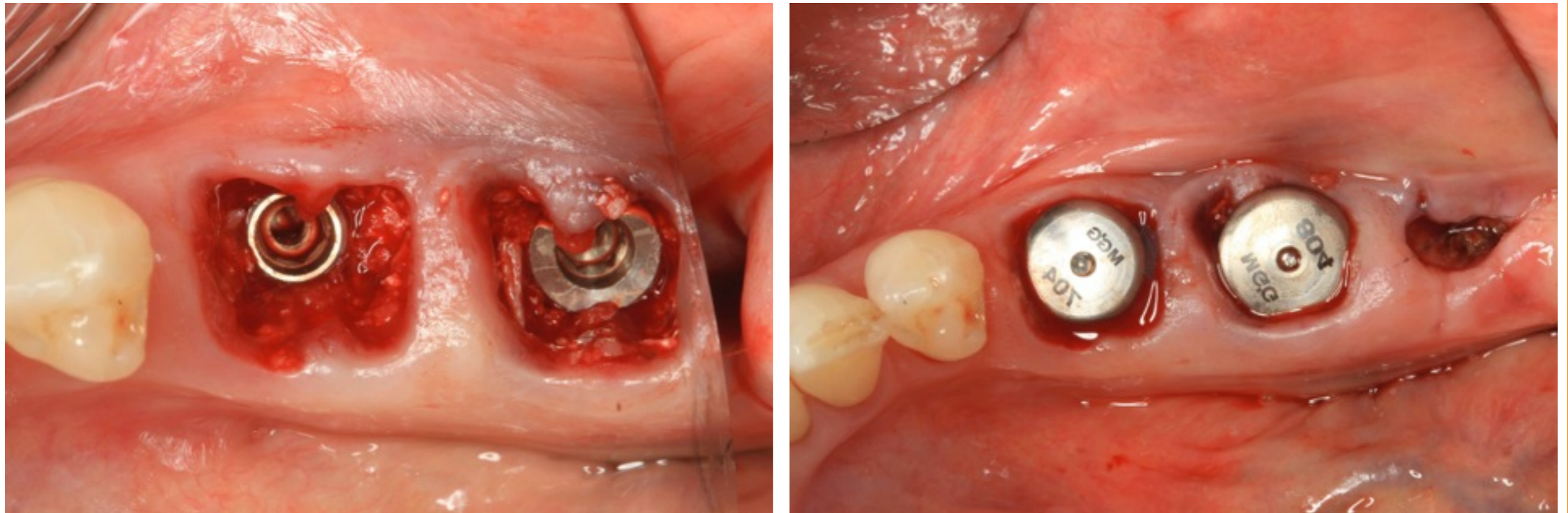
Radiographic Examination



Treatment Plan

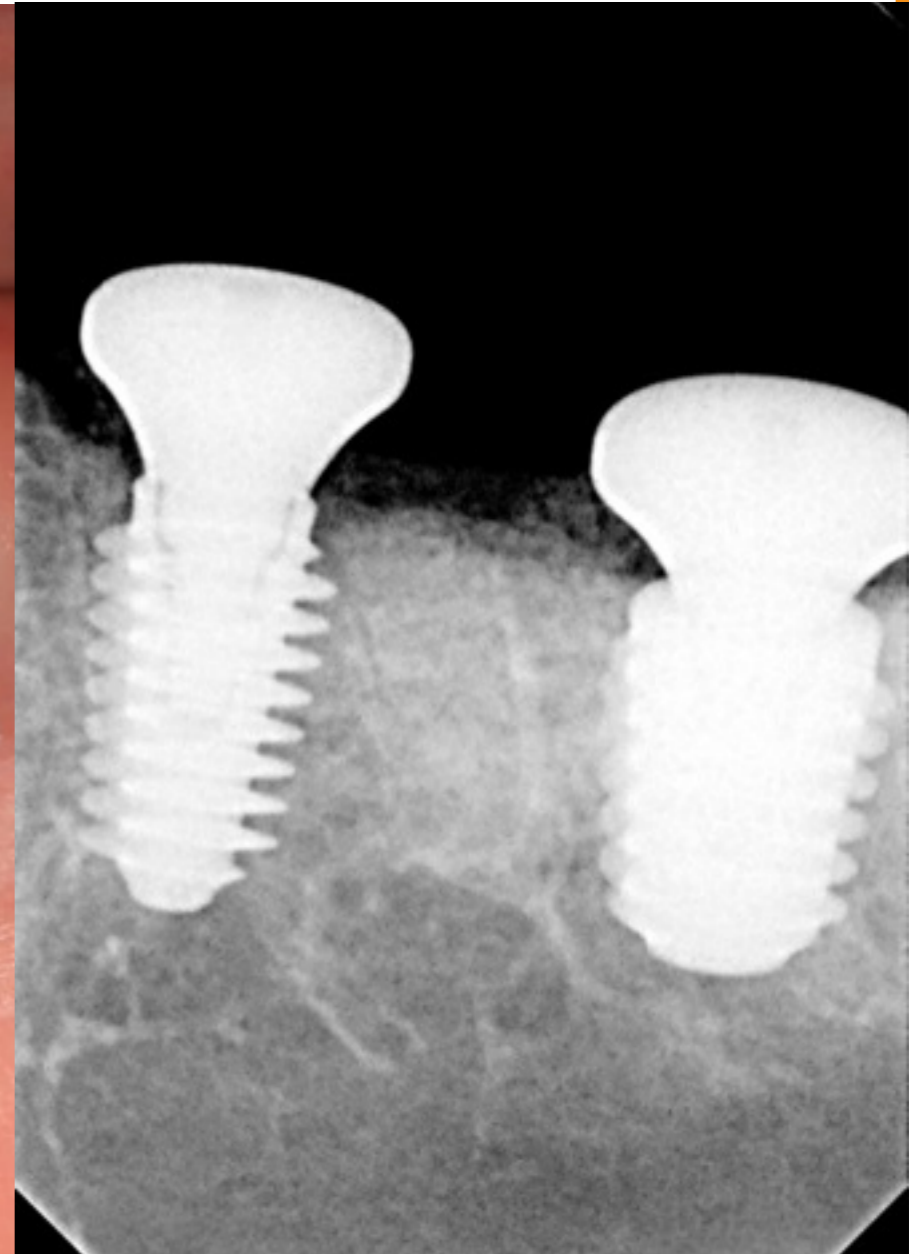
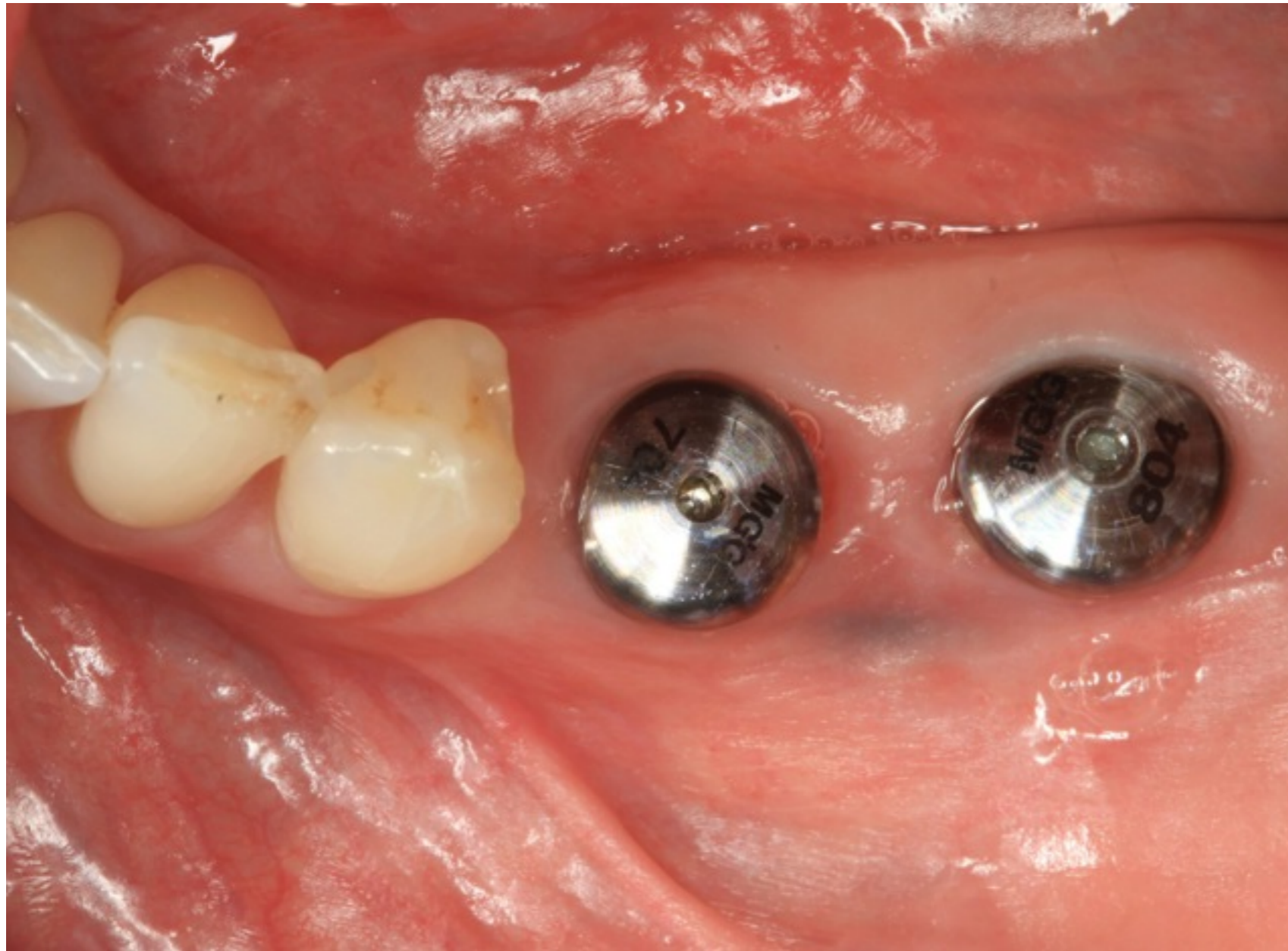
- The possible root canal therapy and crown lengthening and post core crowns were discussed as an alternative option but due to caries susceptibility of the patient we decided with the patient that the ideal treatment plan for her was the implants
- Extraction of teeth and placement of implants in the 36 and 37 area. The 38 would be removed as it was non functional

Treatment

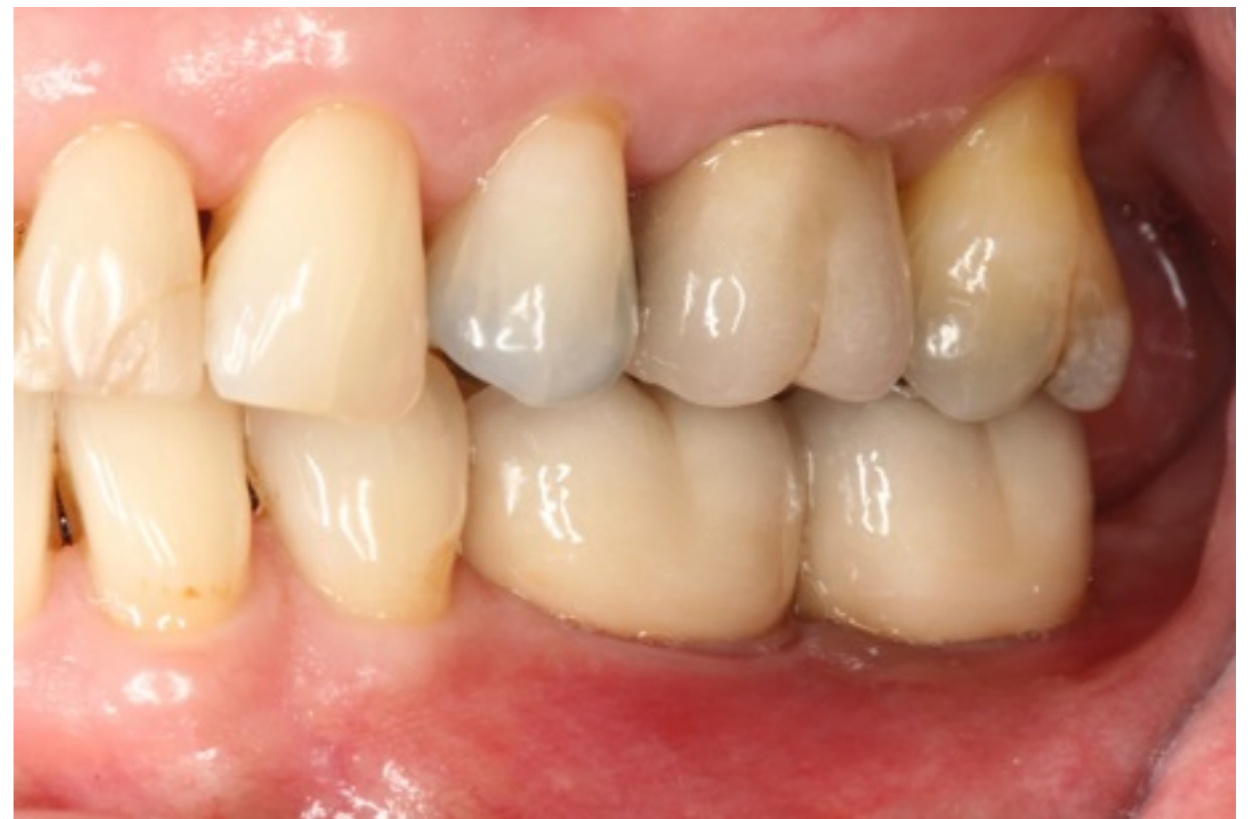
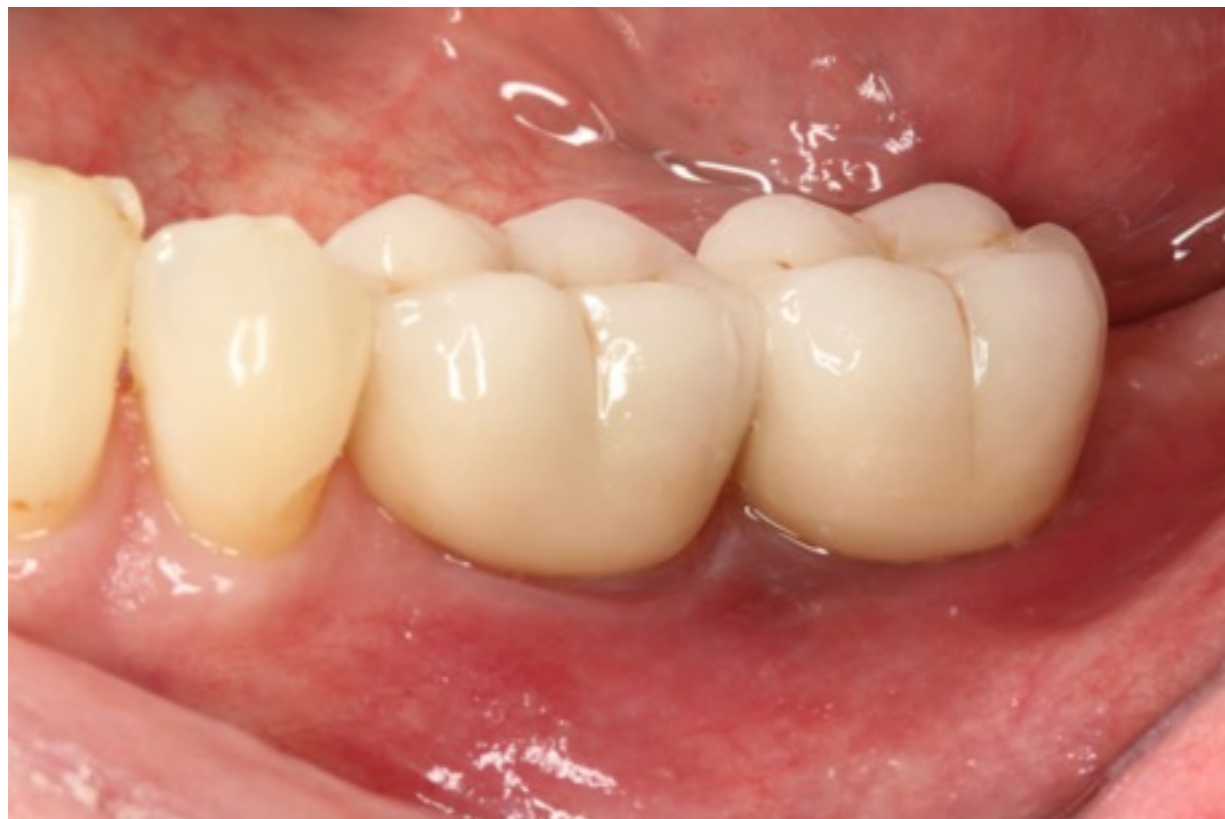
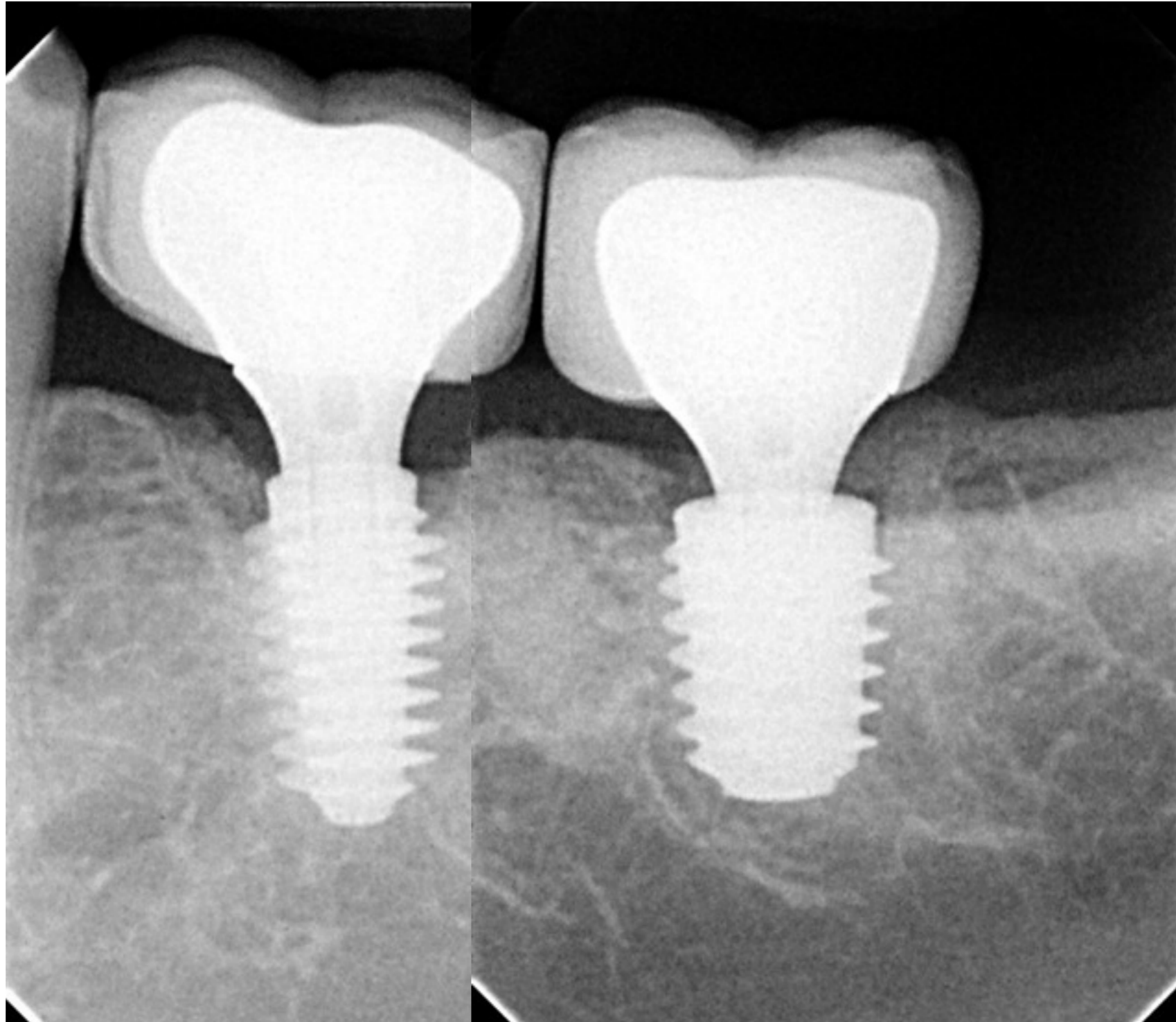
Extraction of the 36, 37 and 38. 2 Anyridge implants were placed and achieved excellent primary stability due to the thread design. The jump gap was filled with porcine xenograft and healing abutments placed that were as large as possible so as to close the extraction socket.

Integration check at 2 months



Final Restoration 6months Post op





Excellent Bone maintenance 6 months post op