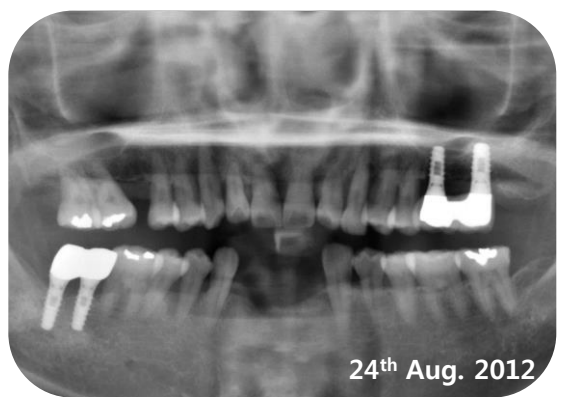

# Mini<sup>TM</sup>

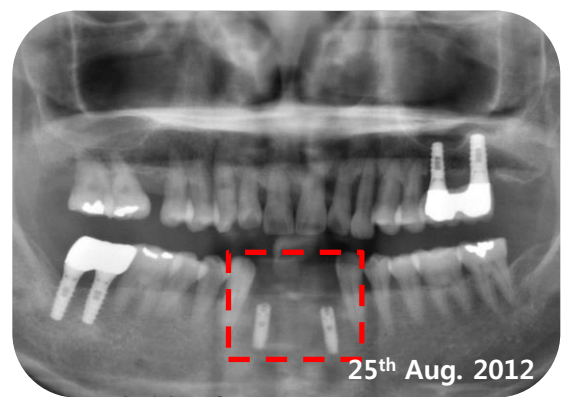
## CLINICAL CASE REPORT

- Dr. Kyung Ho, Ryoo (Gwangju MirDental Clinic)
- Dr. Sang Hyung, Woo (Washington Dental Clinic)
- Dr. Young Bum, Choi (Herb Dental Clinic)

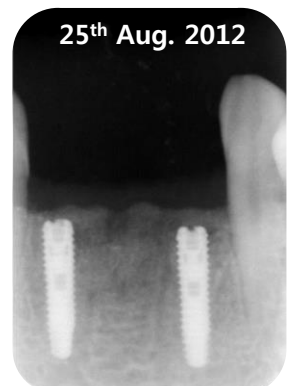
### ■ Clinical Case I -1. Dr. Kyung Ho Ryoo (Gwangju MirDental Clinic)



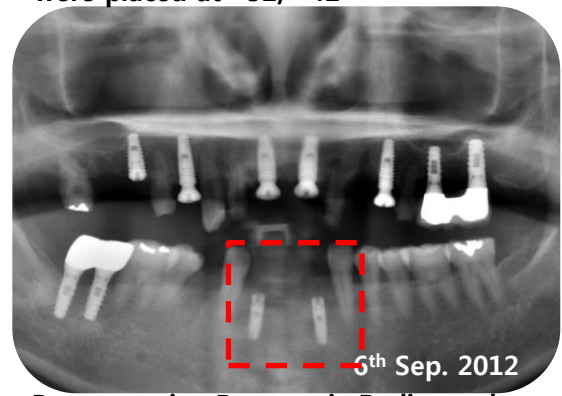
Preoperative Panoramic Radiograph



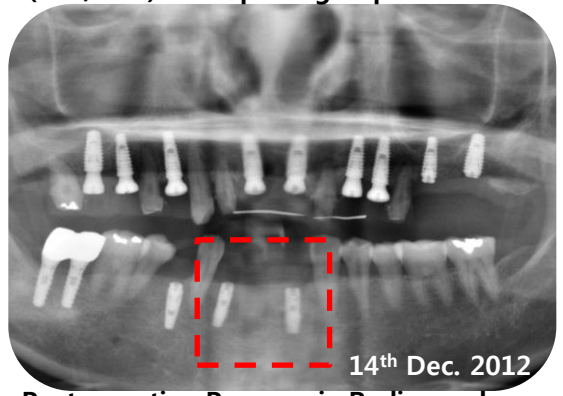
Two MiNi implants[3.0(D) X 11.5(L)mm] were placed at #32, #42



Postoperative intraoral Radiograph (#32, #42) After placing implants

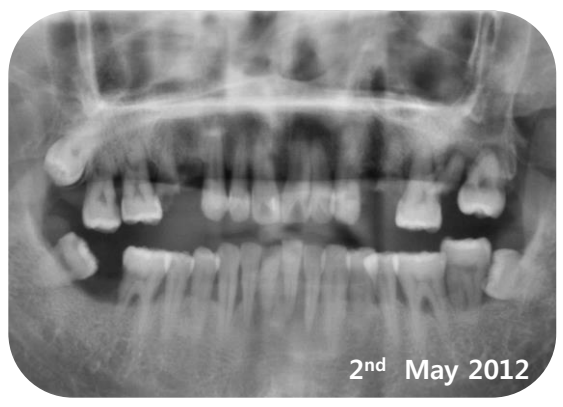

Postoperative Panoramic Radiograph (1 month later)

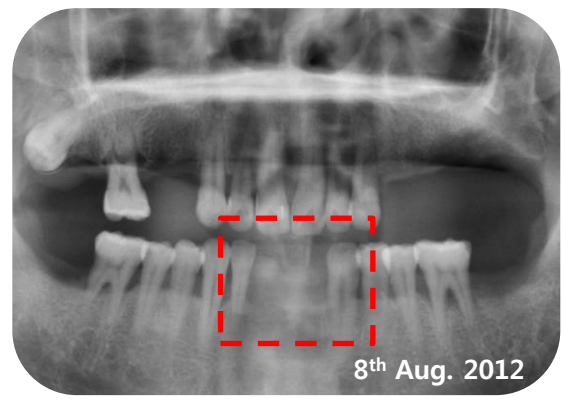


Postoperative Panoramic Radiograph (3 months later)

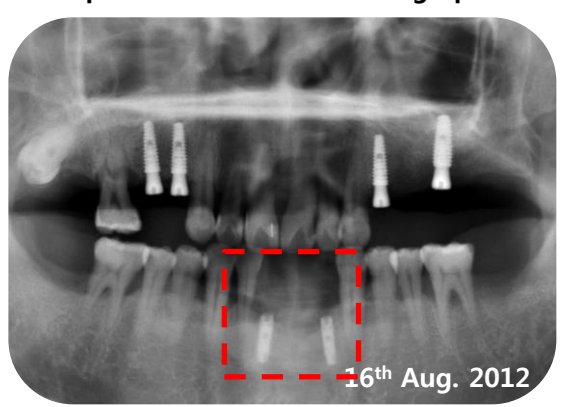
■ Clinical Case I -2. Dr. Kyung Ho Ryoo (Gwangju MirDental Clinic)



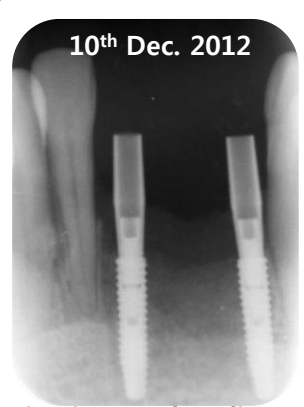
Preoperative Panoramic Radiograph



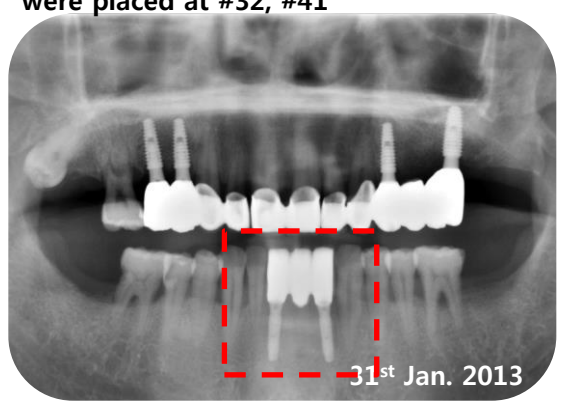
#31, #32, #41 - extraction



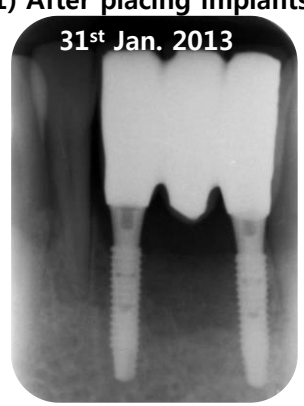Two MiNi implants[3.0(D) X 11.5(L)mm] were placed at #32, #41



Postoperative intraoral Radiograph (#32, #41) After placing implants

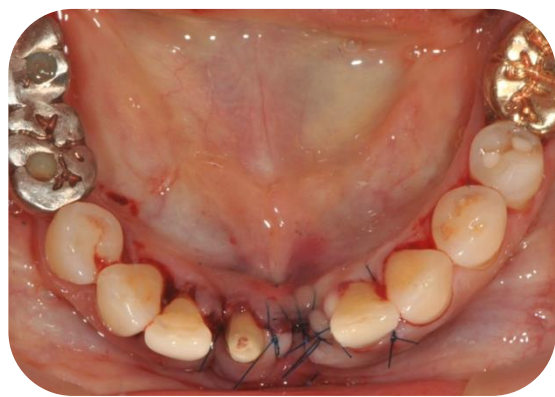

Postoperative Panoramic Radiograph (Placing the final restoration)

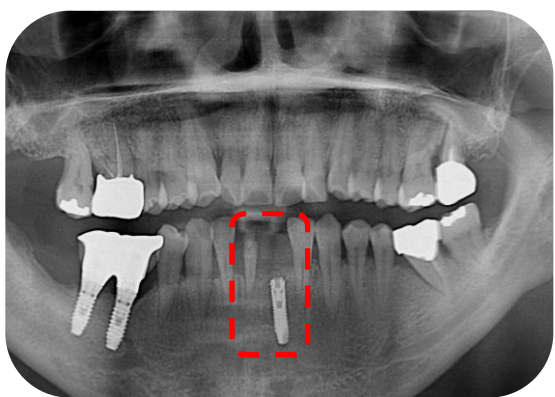


Postoperative intraoral Radiograph

■ Clinical Case II-1. Dr. Sang Hyung Woo (Washington Dental Clinic)

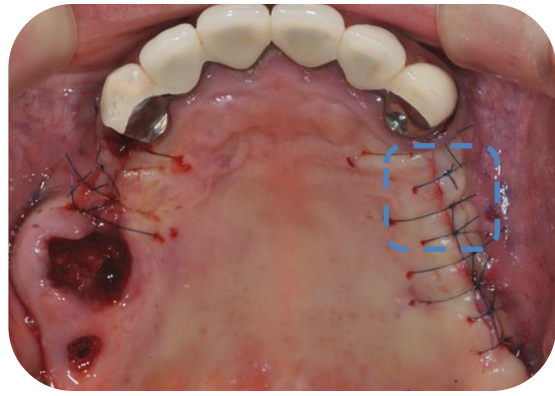


Postoperative Photograph (Mandible)

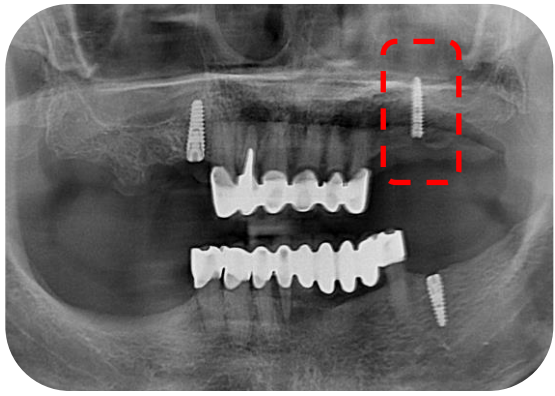


Postoperative Panoramic Radiograph.  
One MiNi implant[3.0(D) X 13.0(L)mm]  
was placed at #31

■ Clinical Case II-2. Dr. Sang Hyung Woo (Washington Dental Clinic)

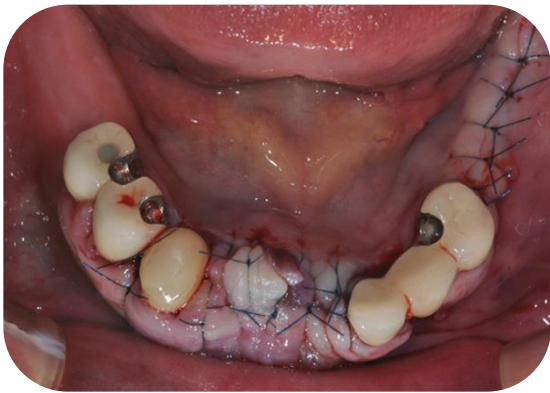

This Patient's teeth#16, #17 needed to  
be extracted. So pulled them out &  
placed AnyRidge[3.5(D) X 11.5(L)mm]  
at #15, MiNi implant[3.25(D) X  
11.5(L)mm] at #25  
- Postoperative Photograph (Maxilla)

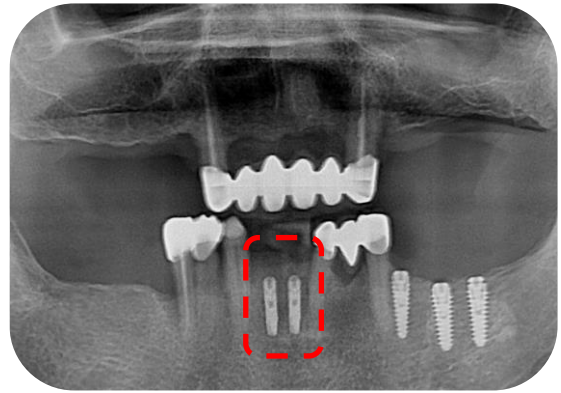


Postoperative Panoramic Radiograph.

■ Clinical Case II-3. Dr. Sang Hyung Woo (Washington Dental Clinic)

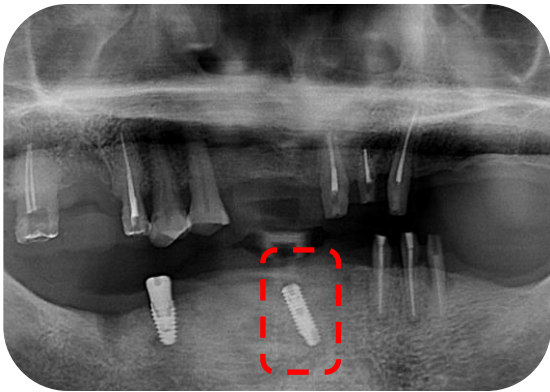


Postoperative Photograph (Mandible)



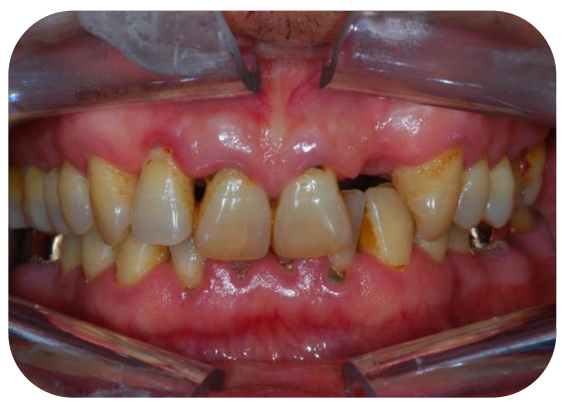Postoperative Panoramic Radiograph.  
Two MiNi implants[3.0(D) X  
11.5(L)mm] were placed at #31, #42

■ Clinical Case II-4. Dr. Sang Hyung Woo (Washington Dental Clinic)

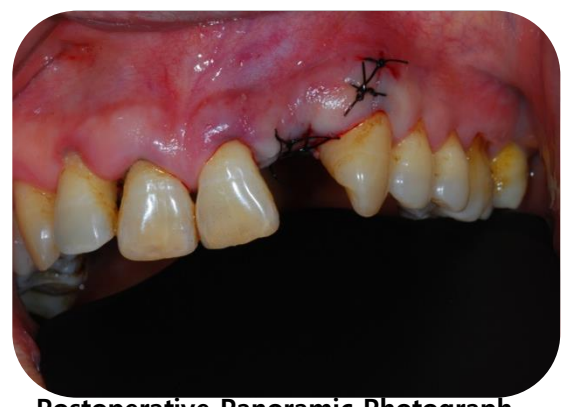

Postoperative Panoramic Radiograph.  
One MiNi implant[3.25(D) X 11.5(L)mm]  
was placed at #41

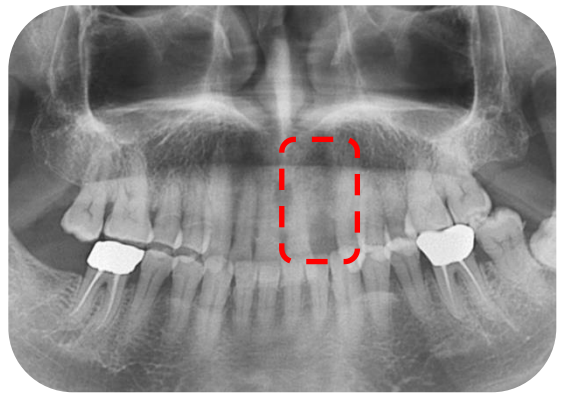
### ■ Clinical Case III-1. Dr. Young Bum Choi (Herb Dental Clinic)



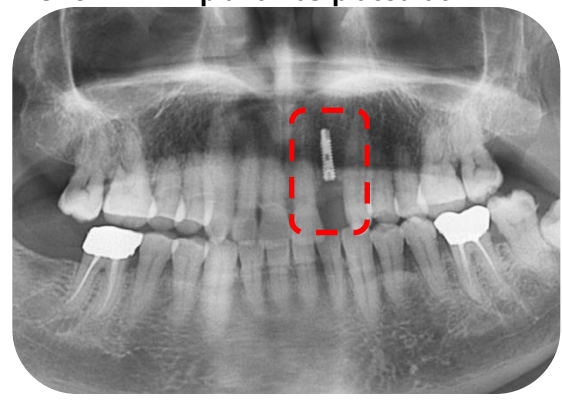
Preoperative Panoramic Photograph



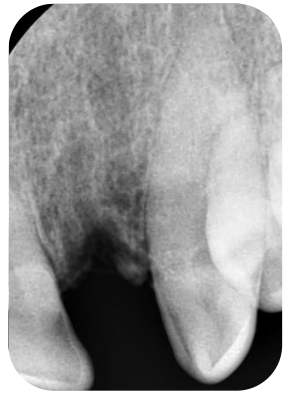Postoperative Panoramic Photograph  
One MiNi implant was placed at #21



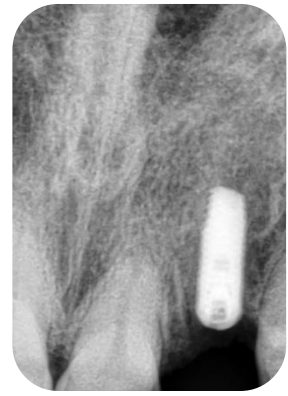Preoperative Panoramic Radiograph



Postoperative Panoramic Radiograph

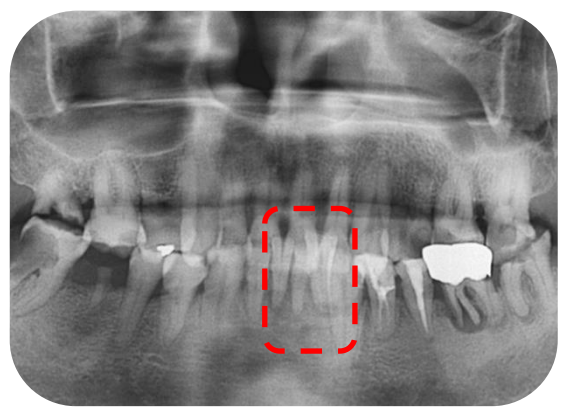


Preoperative Intraoral Radiograph

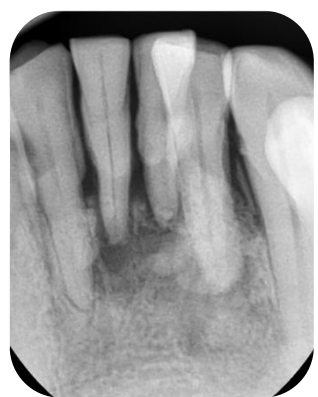

Postoperative Intraoral Radiograph

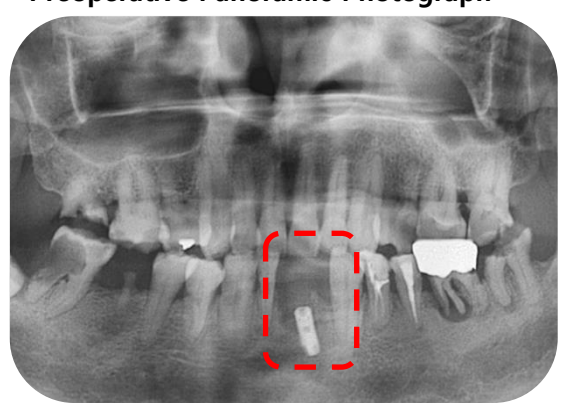
### ■ Clinical Case III-2. Dr. Young Bum Choi (Herb Dental Clinic)



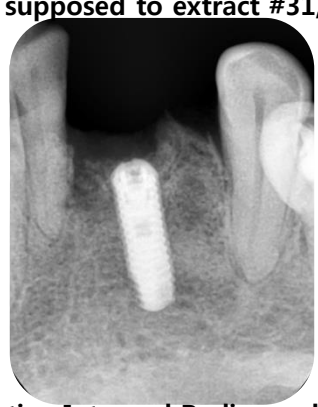Preoperative Panoramic Photograph



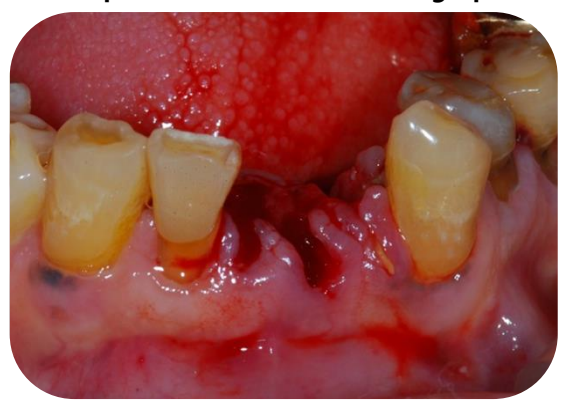
Preoperative Intraoral Radiograph. This Patient is supposed to extract #31, #32, #41



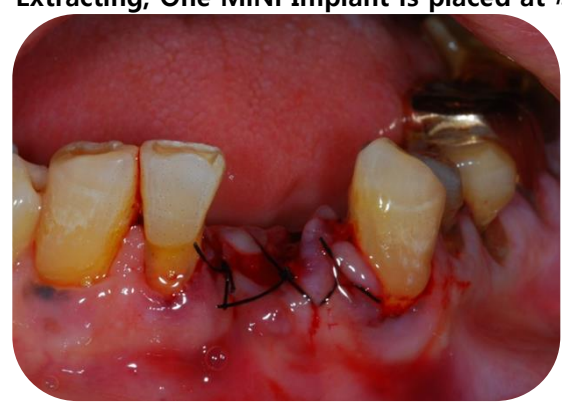
Postoperative Panoramic Radiograph



Postoperative Intraoral Radiograph. After Extracting, One MiNi Implant is placed at #31.



Preoperative Intraoral Photograph



Postoperative Intraoral Photograph